

*Original Article*

## Polyurethane-Coated Silicone Gel Breast Implants Used for 18 Years

Guillermo Vázquez, M.D., and Andrea Pellón, M.D.

Aesthetic Chapter Director of Plastic Surgery, IberoLatinamerican Federation

**Abstract.** This study aimed to present an update on the use of polyurethane-coated silicone gel breast implants. After 18 years of experience using these implants and 1,257 surgically treated patients, the authors can draw some new conclusions. Their postoperative follow-up evaluation of 300 patients for 5 years, 250 patients for 10 years, and 180 patients for 15 years has shown the lowest incidence of fibrous capsular contraction (1%) with these implants.

**Key words:** Breast augmentation—Low capsular contraction—Polyurethane breast implants

Since the study published by Ashley [1,2] in 1970 on implants coated with polyurethane that have a Y-shaped septum, excellent cosmetic results have been achieved with this type of implant, and the incidence of fibrous capsular contraction has been low [4,8–13,16,18–22,24–28,30,31].

In the years after this study, other reports on the use of these implants were published, and several modifications were introduced with regard to coating, gel density, implant profile, and surgical plane. All such variations resulted in better aesthetic outcomes and better results after mastectomy reconstruction [14,29,34].

In 1984, studies performed by Brand [6] with mice showed that polyurethane causes an antigen–antibody (Atg-Atb) reaction, with migration of macro-

phages and giant multinucleate cells, which phagocytize or surround the polyurethane fragments, forming microcapsules that are later replaced by fibroblasts and collagen. These microcapsules trigger a process of slow fibrotic growth from the polyurethane structure toward the periphery, thus hindering fibrous capsular contraction.

A study published by Smahel [36] in 1987 described the histologic characteristics of the capsule formed around the polyurethane-coated implants, and postulated that the material underwent breakdown and was partially incorporated into the capsule.


In 1994, Bucky [7] concluded that the capsules formed around textured saline implants were significantly firmer and less compliant than those of polyurethane-coated implants. This author further noted that although inflammatory cells were present in the capsules of polyurethane implants, there was less fibrotic tissue and less type 3 collagen than in the capsules of textured implants.

With regard to polyurethane implants, there has been concern about the breakdown products of the material, particularly 2,4-toluenediamine (TDA) [35], which was thought to be potentially carcinogenic. The update published by the Food and Drug Administration (FDA) [15] in 1995 made it clear that these implants were safe because it found extremely low concentrations of TDA (parts per million) in the urine of patients who had received the implants and those who had not received them (control group). No free TDA was found in the blood of implanted patients.

In 1997, Hester et al. [23] published a paper in *Plastic Reconstructive Surgery* (PRS) regarding TDA, which the FDA took as a reference. The conclusions of the FDA were definitely confirmed by Santerre et al. [33], who stated that 2,4-TDA is not a relevant material with regard to toxicity and carcinogenesis.

Presented at the XVI IberoLatinamerican Congress in Buenos Aires, Argentina, March 2006, and the International Society of Aesthetic Plastic Surgery (ISAPS) Congress in Rio de Janeiro, Brazil, 2006

Correspondence to G. Vázquez, M.D., Paraguay 2535 Apt. 8<sup>a</sup> “A”, C1425BRA, Buenos Aires, Argentina; *email*: info@cirugiaplasticagv.com



**Fig. 1.** Old anatomic breast implant and new implant with our modification.

In 1999, our *APS* publication [37] presented a comprehensive historical review and a thorough study on the pathology, immunology, and biochemical aspects of the capsules of these implants. In the study of the capsule performed with optical microscopy, we identified five concentric layers, as follows, from the inside out:


- A simple layer of macrophages, epithelioid cells, and giant cells containing phagocytized foreign bodies
- A layer of tissue with subacute inflammation
- A plasmacytic infiltrate
- A thick layer of fibrous connective tissue
- A layer of lax connective tissue along the breast parenchyma.

Analysis of the exudate performed with May Grunwald-Giemsa staining showed clusters of macrophages. With electron microscopy, foreign bodies were seen in a phase of phagocytosis inside the macrophages. Polyurethane remnants were detected with enzyme breakdown of the capsule using a collagenase. Atomic spectroscopy also detected the presence of silicone. The immunologic study showed the predominance of T-lymphocytes, which is characteristic of chronic inflammatory disorders.

### Materials and Methods

To date, we have implanted a total of 1,257 patients. For this study, we randomly selected 300 patients and included them in a 5-year follow-up protocol, which entailed periodic clinical controls every 3 months as well as annual breast ultrasound and mammography. Of these patients, 250 were followed for 10 years and 180 for 15 years.

The patients answered a questionnaire about changes in shape, consistency, satisfaction, softness of the breast, and increased tension over time. Most of the patients (95%) reported that 45 days after surgery, the breasts became softer, an effect that increased with time.



**Fig. 2.** Our modification of the polyurethane anatomic breast implant.

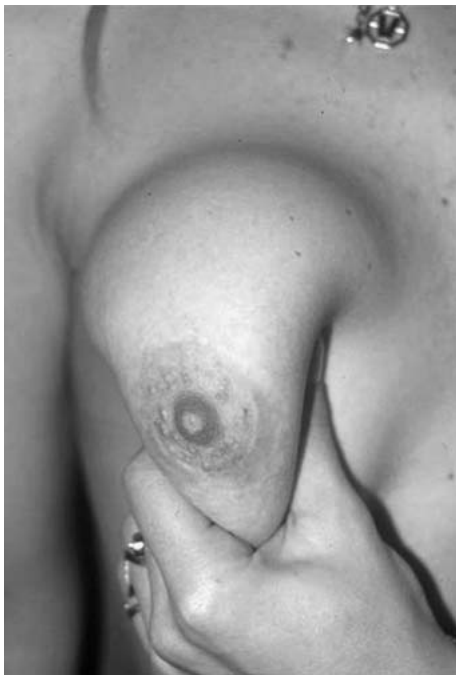Currently, we use only Silimed prostheses (Rio de Janeiro, Brazil), both the anatomic and round models (Pitanguy–Rebello), because the National White and Surgitex prostheses used in the past are no longer manufactured.

With the advent of anatomically shaped implants, another problem became apparent. When patients were in a supine position, the gel shifted toward the lower pole of the breast due to gravity, thus leaving the upper pole with less volume. Under normal conditions, the point of greater implant projection is located behind the areolar complex. In rounded implants, this point is located halfway in the longitudinal axis, so that the gel spreads proportionately, with 50% in the upper pole and 50% in the lower pole. By contrast, in anatomic implants, the distance between the point of greater projection and the lower and upper edges is 30% and 70% of the implant length, respectively. Consequently, the gel is located mainly in the lower pole, and the upper pole lacks adequate volume. Later, with the advent of cohesive gels, this problem appeared to be solved, but very often, the upper pole also lacked projection. This led to frequent complaints from patients who had received anatomic implants.

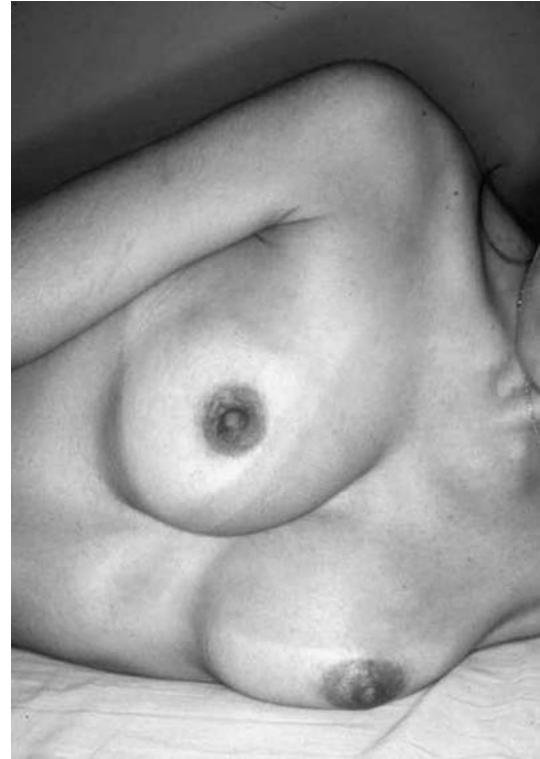To avoid this problem, we developed an anatomically shaped polyurethane-coated silicone gel implant [38]. Its greatest projection is at a distance equivalent to 40% of its length, counting from the lower edge



**Fig. 3.** View when the polyurethane disappears. Model implant: Pitanguy-Rebello, Silimed.



**Fig. 4.** The breast is soft after the 45 days, and this effect increases with time.



**Fig. 5.** Natural movement.



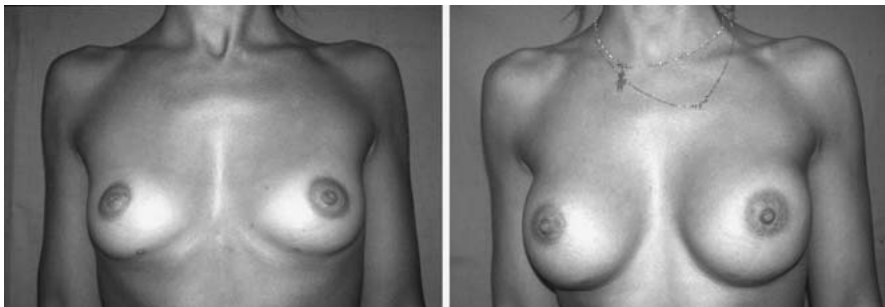
**Fig. 6.** The implant behaves as a textured implant after the polyurethane foam disappears.

(Fig. 1). This implant contains 12.5% more silicone gel, which is very cohesive at the implant's usual manufacturing volume. This provides the implant with greater protrusion and a better angle in the upper pole.

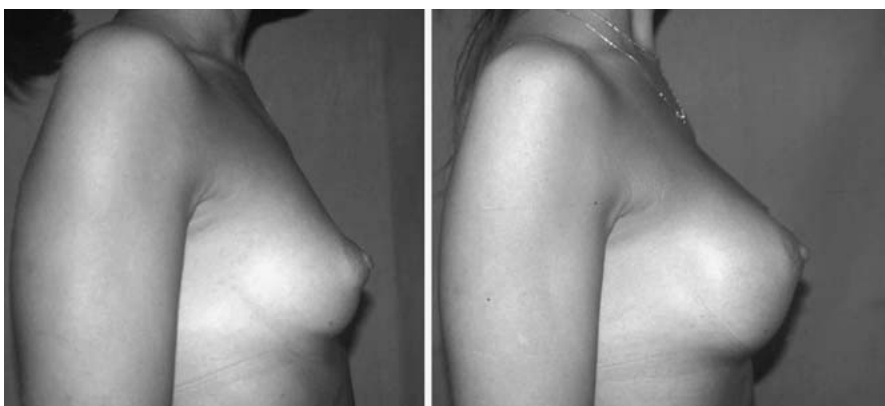
The angle formed by the base and the dome of the implant in the upper pole was increased by 15°. Additionally, the base was reduced by 15 mm to enhance its projection. With these modifications, we were able to overcome the problems previously encountered with anatomic implants (Fig. 2). The use of our anatomic implant provides the breast with a more natural shape and gives better definition to the upper quadrants.

We subjected the implants to rupture tests because addition of the gel had increased their tension. The results obtained with these tests did not show any changes in the implant, and no risk of rupture was observed. Notably, Silimed follows the CEN procedures (European Standardization Committee), norm EN 12180 on Specific Requirements for Breast Implants approved October 29, 1999.

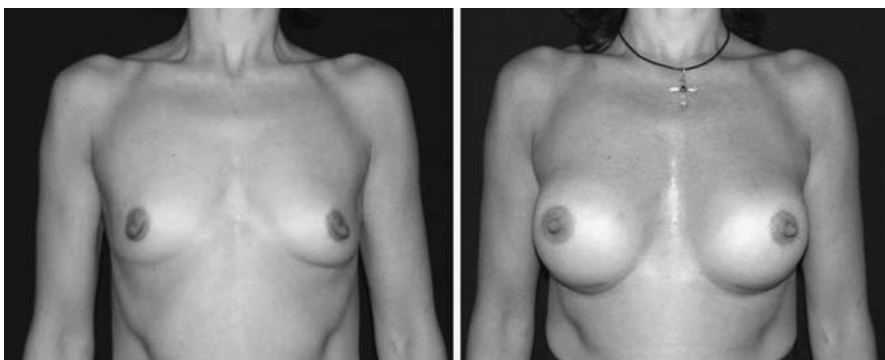
With regard to the surgical procedure, we have implemented certain modifications since our previous communication. First, we have replaced the iodine-povidone solution with saline solution for immersion of the implants before their inclusion.



**Fig. 7.** Frontal view before and after surgery.



**Fig. 8.** Right profile before and after surgery.



**Fig. 9.** Frontal view before and after surgery.

Saline solution is a nonirritant, and its use also helps to avoid potential allergic reactions to iodine.

The surgical approach was periareolar in 80% of the cases and submammary in the remaining 20%, depending on the diameter of the areola, the presence of prior surgeries, and the patient's wishes. The surgical plane was retroglandular, and the upper pole of the prosthesis was contained in the subfascial plane.

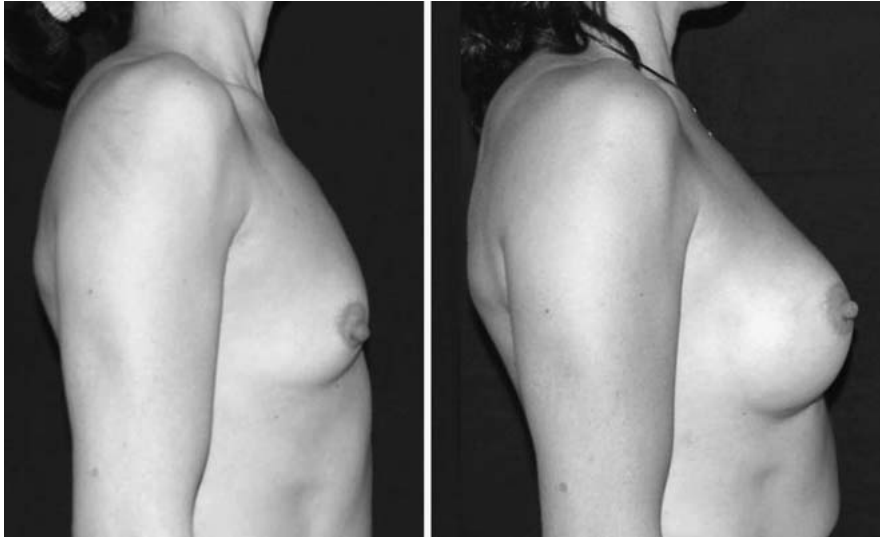Currently, we dissect a wide pocket to avoid formation of folds, and we perform careful hemostasis. We bring the submammary fold downward 1 cm away than when we use textured or smooth implants. The "Velcro effect" of polyurethane implants tends to elevate them. We close the wound in an airtight manner to avoid any type of contamination or fistulization. Our current practice is to begin with breast mobilization 10 days after surgery.

## Results

The patients have been very pleased with the surgical result and with the softness of the breast over time.

Using the Baker classification of capsular contraction, we found an approximate 1% incidence of fibrous capsular contraction. With regard to complication, we found rates similar to those reported in our first article: hematoma (1.2%), seroma (2%), and infection caused by *Staphylococcus epidermidis* (three cases). No cases of late seroma were observed with the use of these prostheses.

It also is notable that we have not seen any cases of cold breast (temperature drop of more than 2°C). This is a frequent complaint among patients with other types of implants. We believe it is caused by the chronic inflammatory reaction.



**Fig. 10.** Right profile before and after surgery.

### Discussion

With the first implants (National White and Surgitex, California, USA), the polyurethane foam was thicker than that used currently in the Silimed implants and was fixed with adhesive. Currently, it also is vulcanized. The changes introduced have brought about four advantages:

1. Detachment of the implant's polyurethane foam no longer occurs, which in the past frequently gave rise to two capsules.
2. Once the polyurethane disappears, the elastomere retains the imprint of the foam and the implant behaves as a textured implant (Fig. 3).
3. The incidence of skin rash, which occurred in some patients, has been markedly reduced because it probably was caused by a reaction to the adhesive rather than to the foam itself.
4. The gel's cohesivity is another advantage of the new implants over the old ones.

### Conclusions

After using the polyurethane-coated breast implants for 1,257 patients over 18 years, we have reached the following conclusions:

- Initially, during the first 6 weeks after surgery, an increase in breast tension is observed. Later, the breasts become softer. This effect increases with time, until their appearance becomes natural (Fig. 4).
- One particular feature is that the implant remains behind the mammary gland and follows it in all its natural movements instead of displacing itself freely throughout the capsular

space, as seen with smooth implants and, less often, with textured implants (Fig. 5).

- In most cases, the polyurethane foam coating begins to disappear about 2 years after surgery. Because the implants currently used have a vulcanized coating, when such coating disappears, the implant behaves as a textured implant. The imprint of the foam on the surface causes a roughness that can be seen macroscopically (Fig. 6).
- Our studies of the capsule have confirmed that part of the polyurethane remains in the capsule. The capsular microscopic architecture is completely different from that of the capsule of smooth and textured implants because the collagen is not organized in a linear and parallel manner. Rather, its fibers are interwoven. This occurs mainly because there are polyurethane remnants in the capsule.
- We recommend placing the upper portion of the implant, either the anatomic or rounded model, in a subfascial position. This allows for an adequate dissection plane and a similar thickness in all its extent, thus preventing the appearance of rippling. We are not convinced of the total subfascial plane approach because we believe it offers no advantages in the lower pole. Furthermore, statistics show it does not affect the incidence of capsular contracture [3,5,17,32,39,40].
- The incision should be closed in an airtight manner in three planes, especially when it is submammary, because it bears much greater pressure due to the weight of the implant.
- We have observed a lower incidence of complications, especially fibrous capsular contraction and late seroma, than observed with the use of

other implants. This lower incidence is due to the special architecture of the capsule that is formed, which results from the presence of the polyurethane in the coating.

Our wide experience shows that although the use of polyurethane-coated silicone gel breast implants can generate some difficulties for insufficiently experienced surgeons in the beginning, if a correct technique is observed, once the learning curve is surpassed, excellent results are achieved, even superior to those achieved with other types of implants. These implants confer greater naturalness to the breast and have a lower incidence of complications (Figs. 7–10).

Currently, given our wide experience with the use of polyurethane-coated silicone gel implants, we may state they are the best option for augmentation mammoplasty, and have the lowest incidence of fibrous capsular contraction (1%).

## References

- Ashley F: A new type of breast prosthesis. *Plast Reconstr Surg* **45**:421, 1970
- Ashley F: Further studies on the Natural-Y breast prosthesis. *Plast Reconstr Surg* **49**:414, 1972
- Barbato C, Pena M, Triana C: Augmentation mammoplasty using the retrofascia approach. *Aesth Plast Surg* **28**:148, 2004
- Barone F, Perry L, Keller T, et al.: The biomechanical and histopathology effects of surface texturing with silicone and polyurethane in tissue implantation and expansion. *Plast Reconstr Surg* **90**:77, 1992
- Benito-Ruiz J: Subfascial breast implant. *Plast Reconstr Surg* **113**:1088, 2004
- Brand G: Foam-covered mammary implants. *Clin Plast Surg* **73**:498, 1984
- Bucky L, Ehrlich P, Sohoni, et al.: The capsular quality of the saline-filled smooth silicone, textured silicone, and polyurethane implants in rabbits: A long-term study. *Plast Reconstr Surg* **93**:1123, 1994
- Capozzi A: Polyurethane-covered gel mammary implants. *Plast Reconstr Surg* **69**:904, 1982
- Capozzi A, Pennisi V: Clinical experience with polyurethane-covered gel-filled mammary prosthesis. *Plast Reconstr Surg* **68**:512, 1981
- Cocke W, Leathers H, Lynch J: Foreign body reactions to polyurethane covers of some breast prosthesis. *Plast Reconstr Surg* **56**:527, 1975
- Cohney B, Cohney T, Hearne V: Nineteen years experience with polyurethane foam-covered mammary prosthesis: A preliminary report. *Ann Plast Surg* **27**:27, 1991
- Dolsky RL: Inserting the Mème prosthesis. *Plast Reconstr Surg* **76**:974, 1985
- Dolsky RL: Polyurethane-coated implants. *Plast Reconstr Surg* **76**:974, 1985
- Eyssen JE, Von Werssowetz AJ, Middlenton GD: Reconstruction of the breast using polyurethane-coated prosthesis. *Plast Reconstr Surg* **74**:415, 1984
- Food and Drug Administration (FDA): Update: Study of TDA released from polyurethane foam-covered breast implants, June 27, 1995
- Gasperoni C, Salgarello M, Gargani G: Polyurethane-covered mammary implants: A 12-year experience. *Ann Plast Surg* **29**:303, 1992
- Graf RM, Bernardes A, Rippel R, Araujo LR, Costa Damio MD, Auersvald A: Subfascial breast implant: A new procedure. *Plast Reconstr Surg* **111**:904, 2003
- Handel N, Cordray T, Gutierrez J, et al.: A long-term study of outcomes, complications, and patient satisfaction with breast implants. *Plast Reconstr Surg* **117**:757–767, 2006
- Handel N, et al.: Comparative experience with smooth and polyurethane breast implants using the Kaplan–Meier method survival analysis. *Plast Reconstr Surg* **88**:475, 1991
- Herman S: The meme implant. *Plast Reconstr Surg* **73**:411, 1984
- Hester R, Cukic J: Use of stacked polyurethane-covered mammary implants in aesthetic and reconstructive breast surgery. *Plast Reconstr Surg* **88**:503, 1991
- Hester R, Nahai F, Bostwick J, et al.: A 5-year experience with polyurethane-covered mammary prosthesis for treatment of capsular contracture, primary augmentation mammoplasty, and the breast reconstruction. *Clin Plast Surg* **15**:569, 1988
- Hester R, et al.: Measurement of 2,4-toluenediamine in urine and serum samples from women with meme or replicon breast implants. *Plast Reconstr Surg* **100**:1291–1298, 1997
- Hoefflin S: Extensive experience with polyurethane breast implants. *Plast Reconstr Surg* **86**:166, 1990
- Luu HM, Hutter JC, Bushar HF: A physiologically based pharmacokinetic model for 2,4-toluenediamine leached from polyurethane foam-covered breast implants. *Environ Health Perspect* **106**:393–400, 1998
- Melmed E: Polyurethane implants: A 6-year review of 416 patients. *Plast Reconstr Surg* **82**:285, 1988
- Melmed E: Treatment of breast contracture with open capsulectomy and replacement of gel prosthesis with polyurethane-covered implants. *Plast Reconstr Surg* **86**:270, 1990
- Pennisi V: Long-term use the polyurethane breast prosthesis: A 14-year experience. *Plast Reconstr Surg* **86**:368, 1990
- Pennisi V: Polyurethane-covered silicone gel mammary prosthesis for successful breast reconstruction. *Aesth Plast Surg* **9**:73, 1985
- Pitanguy I, Brentano J, Castro Ramalho M, et al.: Implante de silicone gel com revestimento de poliuretano. *Rev Brasil Cirurgia* **80**:119, 1990
- Rebello C: Mamoplastia do aumento com próteses mamaria de silicone revestidas de poliuretano. *Rev Brasil Cirurgia Plast* **8**:58, 1993
- Sampaio Goes IC, Lndecker A: Optimizing outcomes in breast augmentation: Seven years of experience with the subfascial plane. *Aesth Plast Surg* **27**:178, 2003
- Santerre JP, Wang FGB, Labor RS: Biodegradation of the microthane polyester polyurethane by the lissome enzyme cholesterol esterase and identification of degradation products. 24th Annual Meeting of the Society for Biomaterials, San Diego, CA, April 1998

34. Schatten W: Reconstruction of breast following mastectomy with polyurethane foam covering gel-filled prosthesis. *Ann Plast Surg* **12**:147, 1984
35. Sinclair T, Kerrigan C, Buntik R: Biodegradation of the polyurethane foam covering of breast implants. *Plast Reconstr Surg* **92**:1003, 1993
36. Smahel J: Tissue reactions to breast implants covered with polyurethane. *Plast Reconstr Surg* **61**:80, 1987
37. Vázquez G: A ten-year experience using polyurethane-covered breast implants. *Aesth Plast Surg* **23**:189–196, 1999
38. Vázquez G: Modification of the anatomic silicone gel implant with polyurethane cover. *Cir Plast Iberolatín-amer* **31**:193–198, 2005
39. Ventura OD: Implantes mamarios subfasciales: Un nuevo concepto. Libro de Comunicaciones del XV Congreso de la FILACP, XXXV Congreso de la SECPRE. Sevilla (España), p. 308, 2004
40. Ventura OD, Marcello G, Gamboa C, et al.: Implantes mamarios en el plano subfascial en reemplazo del bolsillo subglandular: Un cambio lógico. *Cir Plást Iberlatín-amer* **32**:11–16, 2006